



Murdoch
UNIVERSITY

MURDOCH RESEARCH REPOSITORY

<http://researchrepository.murdoch.edu.au>

This is the author's final version of the work, as accepted for publication following peer review but without the publisher's layout or pagination.

Hyndman, T. and Shilton, C.M. (2011) Molecular detection of two adenoviruses associated with disease in Australian lizards. Australian Veterinary Journal, 89 (6). pp. 232-235.

<http://researchrepository.murdoch.edu.au/4453>

Copyright © 2011 The Authors.
It is posted here for your personal use. No further distribution is permitted.

Molecular detection of two adenoviruses associated with disease in Australian lizards

T HYNDMAN^{a*} and CM SHILTON^b

^aMurdoch University, School of Veterinary and Biomedical Science, Murdoch, Western Australia, 6150

^bBerrimah Veterinary Laboratories, Northern Territory Government, GPO Box 3000, Darwin, Northern Territory, 0801

*Corresponding author: t.hyndman@murdoch.edu.au

Abstract

This paper provides the first published description of the pathology and molecular findings associated with adenovirus infection in lizards in Australia. A central netted dragon (*Ctenophorus nuchalis*) exhibited severe necrotising hepatitis with abundant intranuclear inclusion bodies within hepatocytes and rarely within intestinal epithelial cells. Polymerase chain reaction on pooled tissues yielded an amplicon that shared strong nucleotide identity with an agamid adenovirus (EU914203). Polymerase chain reaction on the liver of a bearded dragon (*Pogona minor minor*) with illthrift, coccidiosis, nematodiasis and hepatic lipidosis yielded an amplicon with strong nucleotide identity to a helodermatid adenovirus (EU914207).

Key words adenovirus, lizard, PCR, reptile, Australia

Abbreviations

PCR: Polymerase Chain Reaction

Adenoviruses are non-enveloped double-stranded DNA viruses known to infect every class of vertebrate¹. Adenoviral or adenoviral-like infections have been found in lizards²⁻⁶, snakes^{3,7}, chelonians⁸ and crocodiles⁹. The liver and gastrointestinal tract are two commonly affected anatomical sites¹. Reptilian adenoviruses have been detected in the USA¹, Europe^{2,3,10} and New Zealand⁵ but as yet, there have not been any published reports from Australia. A nested PCR primer set based upon the consensus sequence data from a conserved region of the DNA-dependent DNA-polymerase gene from diverse members of the family *Adenoviridae* has allowed the rapid molecular detection of adenoviruses from a range of samples⁴. This paper describes the discovery of adenoviruses from two genera of Australian lizards. The signalment and history for each case are summarised in Table 1.

All tissue samples submitted for histopathological examination were processed using standard techniques. DNA was extracted from fresh frozen tissue using the Qiagen DNeasy Blood and Tissue Kit (Qiagen Pty Ltd, Doncaster, Victoria) according to manufacturer guidelines. For DNA extraction from formalin-fixed paraffin-embedded material, a fresh microtome was used for each block to cut one to four unstained 6µm sections that were then placed into a single 2 mL microcentrifuge tube. The QIAamp DNA FFPE Tissue Kit (Qiagen Pty Ltd, Doncaster, Victoria) was then used according to the manufacturer's instructions to extract the DNA from these tissue sections. Using the MagMAX™ Viral RNA Isolation Kit (Ambion, Austin, Texas), canine adenovirus type 2 DNA was extracted from a canine vaccine (Protech C3, Fort Dodge, Auckland City, Auckland). The lysis/binding buffer was injected into the vaccine vial to dissolve the freeze-dried powder. The resultant solution was then removed and processing of the sample continued according to the manufacturer's guidelines. Canine adenovirus was used as a positive control for the adenovirus PCR.

Extracted DNA was then used in an adenovirus PCR that has previously been used for the successful identification of reptilian adenoviruses⁴. Briefly, 1µL of extracted DNA, used as a template, was added to 18 µL of Platinum® PCR SuperMix (Invitrogen, Mulgrave, Victoria). PolFouter (5' TNM GNG GNG GNM GNT GYT AYC C) and PolRouter (5' GTD GCR AAN SHN CCR TAB ARN GMR TT) were used at final concentrations of 1 µmol/L. The final reaction volume was 20 µL. Cycling conditions in a thermal cycler (2720 Thermal Cycler, Applied Biosystems, Scoresby, Victoria) consisted of an initial denaturation at 94 °C for 2 mins, followed by 40 cycles of denaturation at 94 °C for 30 secs, annealing at 50 °C for 60 secs and elongation at 72 °C for 45 secs, followed by a final elongation phase at 72 °C for 5 mins. One µL of PCR product was used as template in a second round of PCR using the primer set PolFinner (5' GTN TWY GAY ATH TGY GGH

ATG TAY GC) and PolRinner (5' CCA NCC BCD RTT RTG NAR NGT RA). Conditions for this round of PCR were identical to the first.

PCR products were separated using 2 % agarose gel (w/v dissolved in Tris-Acetate-EDTA buffer) electrophoresis at 80 V for 80 mins and visualised using 0.005 % SYBR safe (v/v in the agarose-Tris-Acetate-EDTA gel; Invitrogen, Mulgrave, Victoria) and a transilluminator (DR88M Dark Reader non-UV Transilluminator; Clare Chemical Research Inc., Dolores, Colorado). Bands of correct size were excised from the gel using a sterile scalpel blade, purified using the Purelink Quick Gel Extraction Kit (Invitrogen, Mulgrave, Victoria) and then directly sequenced on an ABI 3730xl DNA Analyzer (Applied Biosystems, Foster City, California). Primer sequences were excluded from the amplicons, which were then compared to the GenBank database (www.ncbi.nlm.nih.gov/Genbank/index.html). Samples that produced an amplicon of the appropriate size after the nested PCR were then reamplified in a heminested PCR using the primers PolFouter and PolRouter in the first round and PolFinner and PolRouter in the second round. This enables more than 100 bases of additional sequence information to be retrieved from the samples.

The gross and histopathological findings are summarised in Table 1. Adenovirus PCR on the pooled organs (liver, lung, kidney, heart, spleen) from the 2006 netted dragon (*Ctenophorus nuchalis*) case produced an amplicon which shared 98 % nucleotide identity with an agamid adenovirus¹¹ (GenBank Accession Number: DQ077706) over 448 bases and 100 % identity with an agamid adenovirus³ (EU914203) over 271 bases. The segment of adenovirus sequence from the 2009 western bearded dragon (*Pogona minor minor*) liver showed a 99 % nucleotide identity to a helodermatid adenovirus (EU914207) over 250 bases. Amplicon sequence information from the netted dragon and bearded dragon adenoviruses has been deposited into GenBank under the accession numbers HQ005515 & HQ005514 respectively.

As far as the authors could determine, this is the first time that sequence information has been generated that shows strong nucleotide identity to a helodermatid adenovirus but is not from a helodermatid host. Considering lizard adenoviruses are currently being tentatively classified on the basis of strong host-virus association¹², the present finding of a helodermatid adenovirus in an agamid was unexpected. Therefore, it is the belief of the authors that the taxonomic classification of the lizard adenoviruses be changed. We suggest that classification based on the family (eg chameleon and gecko adenoviruses) or genus (eg bearded dragon adenovirus) of the host be revised to a suborder (eg lizard) level of classification. This is fitting with the tentative classification of the snake adenoviruses¹².

To the best of our knowledge, this paper provides the first published description of the molecular detection of reptilian adenoviruses in Australia. Knowledge on the status of reptilian viral diseases in Australia is limited to only a handful of references suggesting such infections and only a few have identified these pathogens using more specific methods such as electron microscopy and/or molecular methods¹³⁻¹⁵. It is our hope that this paper will raise the awareness of Australian practitioners that deal with reptilian patients to the possibility of adenovirus infection.

Several papers have identified adenovirus infections in bearded dragons²⁻⁶. The signalments of many lizards infected with adenovirus are biased towards juveniles^{2,6}, and commonly, ill thrift and concurrent infections, such as coccidia and/or nematode parasites have been found^{3,6}. Hepatic necrosis was the main finding in one of the adenovirus cases presented here, consistent with many other reports^{2,5,6}. Therefore, juvenile dragons with a history of illthrift, with or without other pathogens (such as coccidia or nematodes), or with evidence of hepatic necrosis or hepatitis should raise the suspicion of adenovirus infection in the clinician's mind. In the *P. minor minor* case in which adenovirus was detected in the liver but there was no histological evidence of hepatic necrosis or hepatitis, the role of the adenovirus in this animal's condition remains undefined.

The primer set used in this investigation has been recommended for the discovery of "new" adenoviruses due its exceptional sensitivity across all current genera of *Adenoviridae*¹⁰. At the time of publication, the PCR primer set that has been used in this study is being used in at least two diagnostic laboratories for the diagnosis of adenoviruses from reptilian clinical samples in Florida and Germany. Exporting samples from Australia to international laboratories for diagnosis is problematic as various governmental permits need to be obtained, for example, from the Convention on the International Trade of Endangered Species, the Australian Quarantine and Inspection Service and State or Territory wildlife management agencies. Furthermore, it is becoming increasingly difficult for many overseas laboratories to satisfy the legal requirements for the importation of international samples. Therefore, it is of value for this adenovirus PCR to be available in Australia. Not only will this provide a service that is more accessible to Australian veterinarians but turnaround times for results will also be improved.

In the USA, most inland bearded dragons (*Pogona vitticeps*) that are PCR-tested for adenovirus are positive (Wellehan J, University of Florida, personal communication). By enabling the rapid and specific diagnosis of adenoviruses to be made in this country, the ability to screen both wild and captive Australian reptiles for infectious diseases will be improved. More informed decisions can then be made concerning the health care of these animals.

The authors would like to thank Drs Jodie Low Choy, Mark Bennett, Julia Galvez and Peter Holz who provided valuable assistance by submitting samples or contributing to this manuscript.

References

1. Jacobson ER. Viruses and Viral Diseases of Reptiles. In: Jacobson ER, editor. *Infectious Diseases and Pathology of Reptiles*, CRC Press, Florida, 2007:395-460.
2. Moormann S, Seehusen F, Reckling D et al. Systemic Adenovirus Infection in Bearded Dragons (*Pogona vitticeps*): Histological, Ultrastructural and Molecular Findings. *J Comp Pathol* 2009;141:78-83.
3. Papp T, Fledelius B, Schmidt V, Kaján GL, Marschang RE. PCR-sequence characterization of new adenoviruses found in reptiles and the first successful isolation of a lizard adenovirus. *Vet Microbiol* 2009;134:233-40.
4. Wellehan JFX, Johnson AJ, Harrach B et al. Detection and analysis of six lizard adenoviruses by consensus primer PCR provides further evidence of a reptilian origin for the atadenoviruses. *J Virol* 2004;78(23):13366-9.
5. Julian AF, Durham PJ. Adenoviral hepatitis in a female bearded dragon (*Amphibolurus barbatus*). *N Z Vet J* 1982;30(5):59-60.
6. Kim DY, Mitchell MA, Bauer RW, Poston R, Cho DY. An outbreak of adenoviral infection in inland bearded dragons (*Pogona vitticeps*) coinfecting with dependovirus and coccidial protozoa (*Isospora sp.*). *J Vet Diagn Invest* 2002;14(4): 332-4.
7. Ramis A, Fernandez-Bellon H, Majó N et al. Adenovirus hepatitis in a boa constrictor (*Boa constrictor*) *J Vet Diagn Invest* 2000;12(6): 573-6.
8. Rivera S, Wellehan JF Jr, McManamon R et al. Systemic adenovirus infection in Sulawesi tortoises (*Indotestudo forsteni*) caused by a novel siadenovirus. *J Vet Diagn Invest* 2009;21(4):415-26.
9. Jacobson ER, Gardiner CH, Foggin CM. Adenovirus-like infection in two Nile crocodiles. *J Am Vet Med Assoc* 1984;185(11):1421-2.
10. Benko M, Kajan GL, Janoska M et al. How to Find "New" Adenoviruses. In: *Proceedings of the 7th International Congress of Veterinary Virology*, 2006.
11. Kübber-Heiss A, Benetka V, Filip T et al. First detection of an adenovirus infection in a bearded dragon (*Pogona vitticeps*) in Austria. *Veterinary Medicine Austria (Wiener tierärztliche Monatschrift)* 2006;93(3):68-72.
12. Benko M, Harrach B, Both GW et al. Family Adenoviridae. In: Fauquet CM, Mayo MA, Maniloff J et al., editors, *Virus taxonomy: Eighth report of the international committee on taxonomy of viruses*, 2005: 213-228.
13. Rose K, Montali RJ, Ross T et al. Investigations into Snake Viral Diseases in Australia. In: *Proceedings of the Wildlife Disease Association International Conference*, 2005.
14. Buenviaje G N, Ladds PW, Martin Y. Pathology of skin diseases in crocodiles. *Aust Vet J* 1998;76(5):357-63.
15. Hyatt AD, Williamson M, Coupar BE et al. First identification of a ranavirus from green pythons (*Chondropython viridis*). *J Wildl Dis* 2002;38(2):239-52.

Figure 1. Formalin-fixed liver lobes from Central netted dragon (*Ctenophorus nuchalis*) with adenovirus infection. Note the diffuse fine irregular reticulate pattern produced by alternating pale and darker tissue resulting from areas of necrosis (pale) intermingled with areas of hyperaemia (darker). Scale bar equals 5 mm.

Figure 2. Histology photomicrograph of liver from central netted dragon depicted in Figure 1. Note acute coagulation necrosis involving most hepatocytes and lack of inflammatory response. Several hepatocytes contain large amphophilic intranuclear inclusion bodies (arrows). Scale bar equals 20 µm. (H&E).

Figure 3. Histology photomicrograph of large intestine from central netted dragon depicted in Figures 1 and 2. Note lack of evidence of overt necrosis of mucosal epithelium. Two large amphophilic intranuclear inclusions are present (arrows). Scale bar equals 20 µm. (H&E).

Table 1. Summary of study findings

Year	Species	Animal location	Clinical history	Gross pathology	Histopathology	Adenovirus polymerase chain reaction assay	Comments
2006	Central netted dragon <i>Ctenophorus nuchalis</i>	Darwin, Northern Territory	Recently acquired from another captive collection. Prior history and age unknown. Found dead in enclosure with no premonitory clinical signs.	Diffusely mottled red/tan liver (Figure 1), haemorrhage in intestinal lumen	Severe diffuse necrotising hepatitis with moderate numbers of large amphophilic intranuclear inclusion bodies in hepatocytes (Figure 2). Occasional amphophilic intranuclear inclusions in large intestinal mucosal epithelial cells (Figure 3). A wide range of other tissues examined histologically were unremarkable.	+ve on formalin-fixed paraffin-embedded material	There was no intestinal pathology to suggest a cause for the intraluminal haemorrhage, indicating it may have been due to a coagulopathy resulting from diffuse hepatic necrosis.
2009	Western bearded dragon <i>Pogona minor minor</i>	Perth, Western Australia	Juvenile with illthrift, coccidiosis, nematodiasis. Euthanased. Three in-contact <i>P. minor</i> with similar clinical signs.	Hepatomegaly	Hepatic lipidosis. No cellular inclusions or evidence of hepatic necrosis or inflammation seen.	+ve on fresh-frozen liver	Only the liver was submitted for analysis



Figure 1

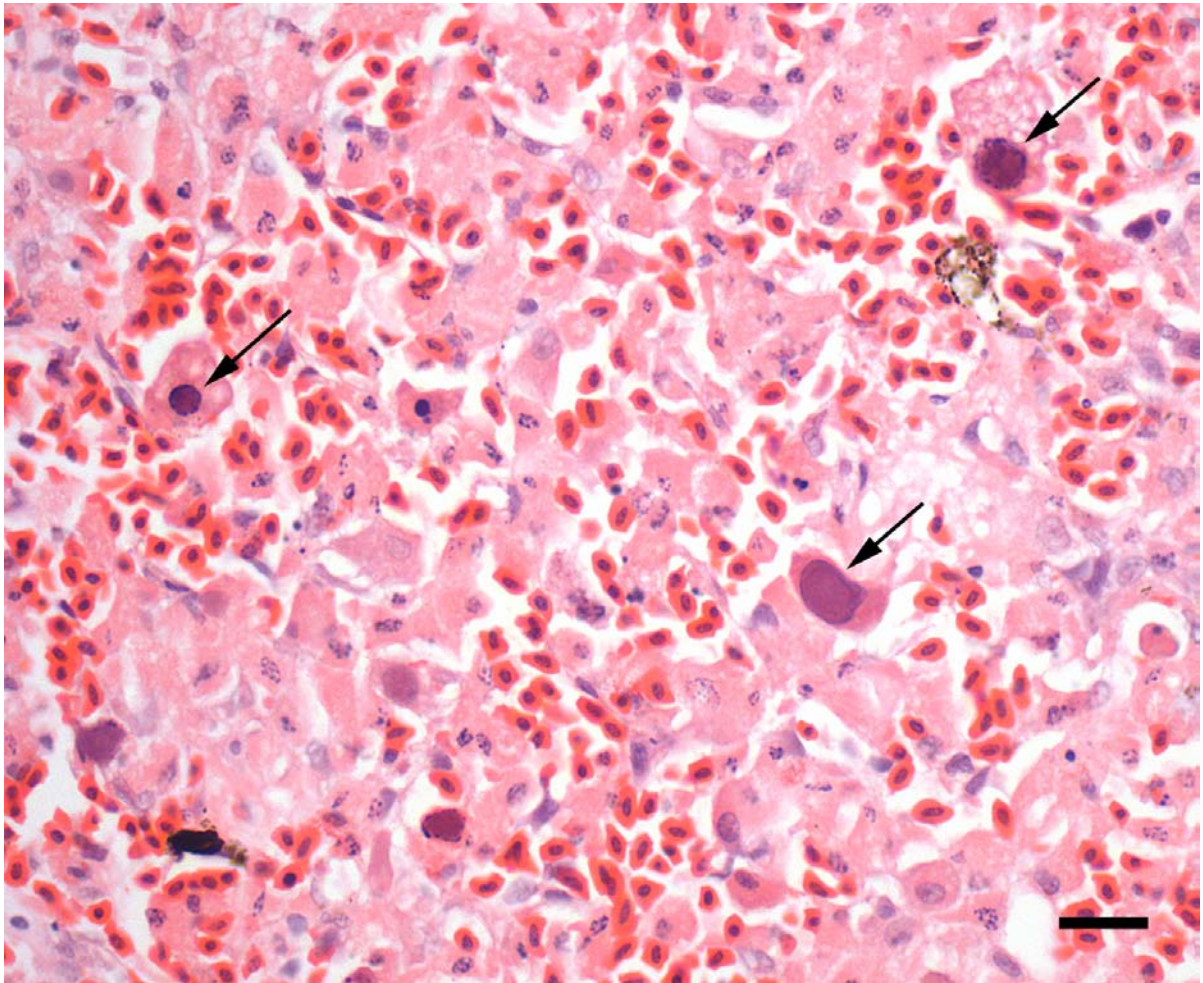


Figure 2

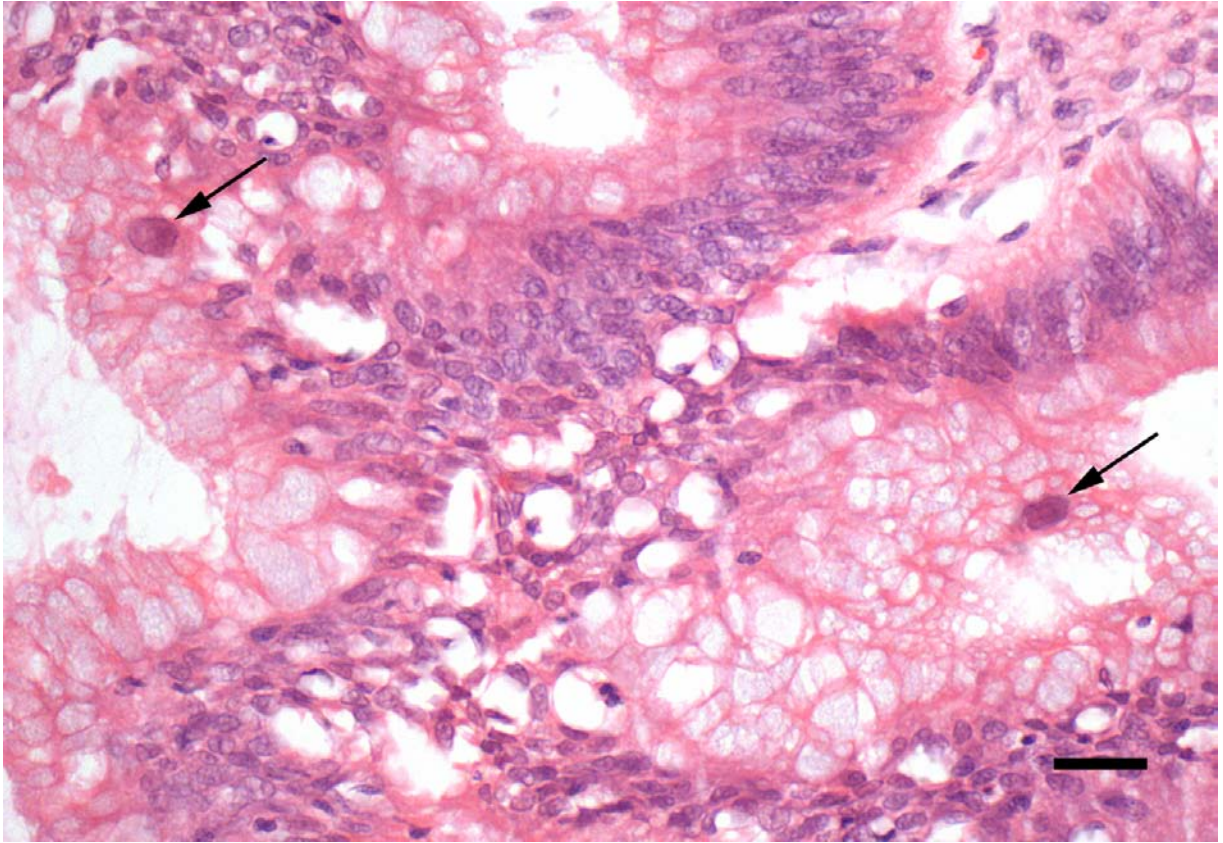


Figure 3