

PARASITIC INFECTION IN A FLOCK OF RUFIOUS-CRESTED BUSTARDS (*EUPODOTIS RUFICRISTA*) IN THE UNITED ARAB EMIRATES

Philip K. Nicholls, B.Sc., B.V.Sc., Thomas A. Bailey, B.Sc., B.V.Sc.,
Lynda M. Gibbons, B.Sc., Ph.D., Arlene Jones, B.Sc., Ph.D., and
Jaime H. Samour, M.V.Z., Ph.D.

Abstract: *Otiditaenia macqueeni*, *Raillietina* sp., *Paronchocerca tonkinensis*, and *Allodapa* sp. were recovered from a group of rufous-crested bustards (*Eupoditis ruficrista*) which died after importation into the United Arab Emirates. Associated findings at postmortem examination included cardiac rupture, weight loss, trichomoniasis, and enteritis. Histologic examinations revealed *Paronchocerca* sp. microfilariae in sections of liver, kidney, lung, and myocardium. *Haemoproteus telfordi* and *H. tenderoi* were identified in blood smears from two birds. These parasites may be a contributing factor in the high mortality of rufous-crested bustards in captivity.

Key words: *Otiditaenia* sp., *Raillietina* sp., *Paronchocerca* sp., *Allodapa* sp., *Haemoproteus* sp., rufous-crested bustard, *Eupoditis ruficrista*.

INTRODUCTION

The rufous-crested bustard (*Eupoditis ruficrista*) is a member of the Otididae family occurring in three separate regions in Africa. In west Africa it occurs from Senegal and Mauritania to Sudan, in east Africa it occurs from South Ethiopia and Somalia southward to Tanzania, and in southern Africa it is found south of a line from south Angola to south Mozambique.¹¹ Rufous-crested bustards inhabit semiarid lands with some cover.⁸ The southern and eastern races are common, but the west African race is rarer and little-known.^{8,11}

Published cases of morbidity and mortality in bustards are scarce,⁵ and, to our

knowledge, the clinical and pathologic aspects of parasitic infestations in rufous-crested bustards have not been described previously. The rufous-crested bustards described in this article were examined by staff of the National Avian Research Centre, United Arab Emirates (UAE), a scientific and conservation organization primarily concerned with conservation of the houbara bustard (*Chlamydotis undulata macqueeni*) but also involved in a captive breeding program for rufous-crested bustards at Al Ain Zoo, UAE. Investigations into the causes of disease in rufous-crested bustards should contribute to the success of captive breeding programs.

CASE REPORTS

In April 1993, 10 rufous-crested bustards were imported from Somalia by a private individual into the UAE. The birds were transported in two woven-reed shopping baskets, and, although no further history was available, it was suspected that the birds had been transported by air. Two birds (Nos. 1 and 2) were dead on arrival at the quarantine facility at Al Ain Zoo, a third bird (No. 3) died in the afternoon of the same day, and a fourth bird (No. 4) died the following day. A fifth bird (No. 5) died 2 days after

From the Animal Pathology Division, Department of Clinical Veterinary Medicine, University of Cambridge, Cambridge, CB3 0ES, England, United Kingdom (Nicholls); the Veterinary Science Department, National Avian Research Centre, Box 45553, Abu Dhabi, United Arab Emirates (Bailey, Samour); and the International Institute of Parasitology, 395A Hatfield Road, St. Albans, Hertfordshire, AL4 0XU, England, United Kingdom (Gibbons, Jones).

Send correspondence to P. K. Nicholls, BSc, BVSc, MRCVS, Dip. RCPATH, Animal Pathology Division, Department of Clinical Veterinary Medicine, University of Cambridge, Madingley Road, Cambridge CB3 0ES, United Kingdom.

arrival, and the remaining five birds were reported to be healthy 1 mo later. At the request of the importer, all dead birds were submitted to us for postmortem examination to investigate the possible causes of mortality.

Clinical findings and treatments

On arrival at Al Ain Zoo the seven surviving birds were given full clinical examinations. All birds were in poor or emaciated condition as judged by palpation of pectoral muscles. The range in body weights was 413–517 g (mean = 504 ± 56 g). Four birds had yellow caseous necrotic plaques in the oral cavity; wet mounts examined microscopically revealed numerous flagellated protozoa typical of *Trichomonas* sp. One bird was treated for a fractured lateral digit of the left foot and also had a broken toenail on the middle digit of the right foot. No other abnormalities were detected.

As part of a routine preventive medicine program, all birds were treated with 200 µg/kg i.m. ivermectin (Ivomec, Merck, Sharp and Dohme, Hoddesdon, Hertfordshire, EN11 9BU, United Kingdom) 25 mg/kg p.o. mebendazole (Vermox, Janssen Pharmaceuticals, Grove, Wantage, Oxfordshire, OX12 0DQ, United Kingdom), and 0.2 ml i.m. of a multivitamin preparation (Multivet, C-Vet, Bury St. Edmunds, Suffolk, IP33 3SU, United Kingdom). All birds with trichomoniasis received 50 mg/kg p.o. metronidazole benzoate (Flagyl-S, May and Baker, Dagenham, Essex, RM10 7XS, United Kingdom). As a routine prophylactic measure, the drinking water for all birds was medicated with dimetridazole (Emtryl 40%, Rhone Merieux, Harlow, Essex, CM19 5TS, United Kingdom) at a dose of 0.9 g/L of water for 5 days, followed by 0.7 g/L of water for 10 days.

Postmortem examination findings

The two female (Nos. 1, 2) and three male (Nos. 3, 4, 5) birds which died were ex-

amined postmortem using standard techniques.¹⁰ The weight range of the dead birds was 365–513 g (mean = 447 ± 60 g), and all were in poor or emaciated nutritional condition as judged by pectoral muscle examination. One bird (No. 1) had marked hemopericardium secondary to rupture of the right ventricular myocardium. In the right ventricle and pulmonary arteries of three birds (Nos. 1, 3, 4), there were large numbers of nematodes, 3–4 cm in length. Additional nematodes were present in the vena cava and testicular blood vessels of one bird (No. 3). Cestodes were present in the ileum and jejunum of two birds (Nos. 1, 3), and nematodes were recovered from the cecum of these birds. Focal raised, pale lesions typical of trichomoniasis were seen in the oropharynx of birds Nos. 3 and 4. Thickened jejunal mucosa, in the absence of helminths, was seen in one bird (No. 5) which had been given anthelmintic treatment 2 days previously.

Histologic examinations

Microscopic examinations of tissue from the three birds in which *Paronchocerca* sp. were found revealed numerous microfilariae in the arteries and small blood vessels of the lung. There was mild thickening of some of the smaller arterial walls and a prominent accumulation of eosinophils throughout the lung tissue, and occasional foci of mixed inflammation, including numerous eosinophils and macrophages, were present in some sections of lung. There were no signs of thrombosis in the pulmonary vessels. Some macrophages filled with crystalline debris surrounded the larger airways, and this probably represented phagocytosed airborne debris such as small sand particles. Histologic examination of hearts revealed microfilariae in large numbers throughout the microvasculature of the myocardium (Fig. 1). Although there was no obvious tissue reaction to the microfilariae in two of the birds, the bird with a cardiac rupture showed focal areas of prominent myocar-

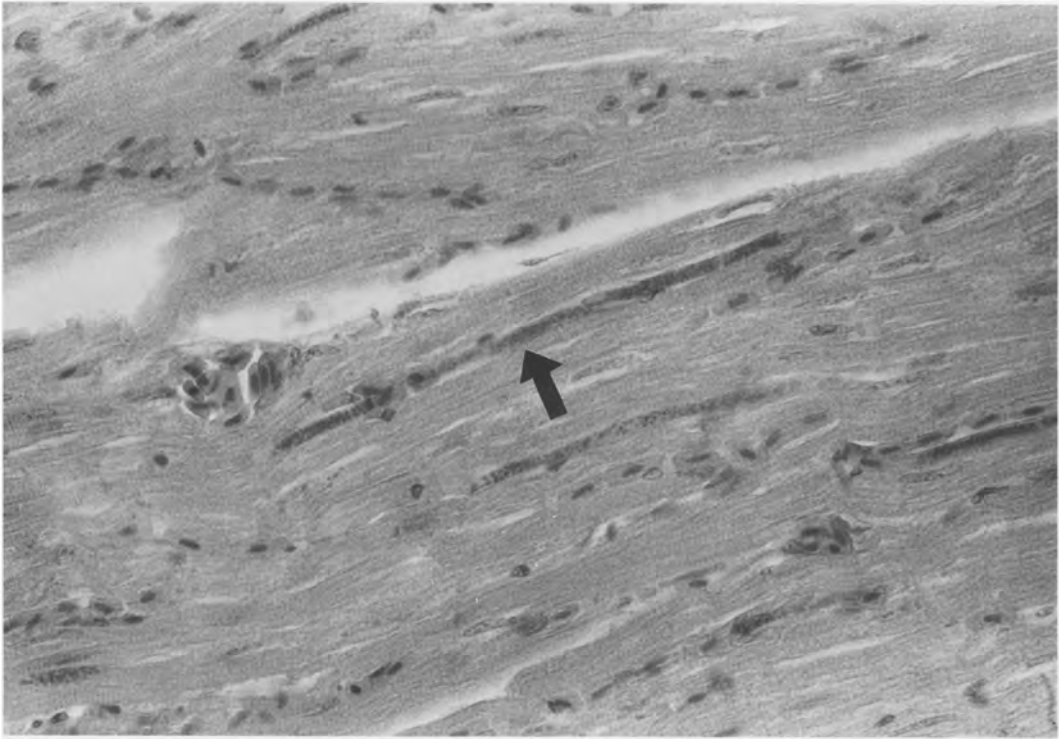


Figure 1. Myocardium with several *Paronchocerca tonkinensis* microfilariae (arrow). No host tissue reaction is apparent in this field. H&E, $\times 400$.

dial degeneration and fibrosis in the right ventricular free wall. Microfilariae were seen in the microvasculature of the liver (Fig. 2) and kidney in these three birds, although no tissue reaction or other lesions were seen. The tissues from the two other birds showed no signs of microfilariae. Sections from different levels of the intestinal tract in all birds showed variable amounts of mononuclear mucosal inflammation, varying from inapparent to moderate in degree, with occasional foci of lymphoid proliferation.

Parasitologic identifications

Whole parasites were preserved in 10% buffered formalin and submitted to the International Institute of Parasitology, St. Albans, Hertfordshire, England, United Kingdom, for identification. Specimens from ileum and jejunum were identified as very early to gravid *Otiditaenia macqueeni*

(Bloch, 1782) and immature specimens of *Raillietina* sp., probably *R. neyrai* (Baer, 1955), both from the family Davaineidae. The parasites found in the heart and vascular system were identified as *Paronchocerca tonkinensis* (Filaroidea: Onchocercidae) (Chow, 1939). There were minor differences in measurements and in the arrangement of one small pair of papillae on the male tail compared to the original description by Chow. The bustard is unlikely to be the natural host for this parasite, which may account for these minor differences. These differences are insufficient to establish a new species, and further studies are required to establish the full host and geographic range of the parasite. The specimens recovered from the cecum were identified as *Allodapa* sp. (Subuluroidea: Subuluridae). Further identification was impossible since all the available specimens were from females.

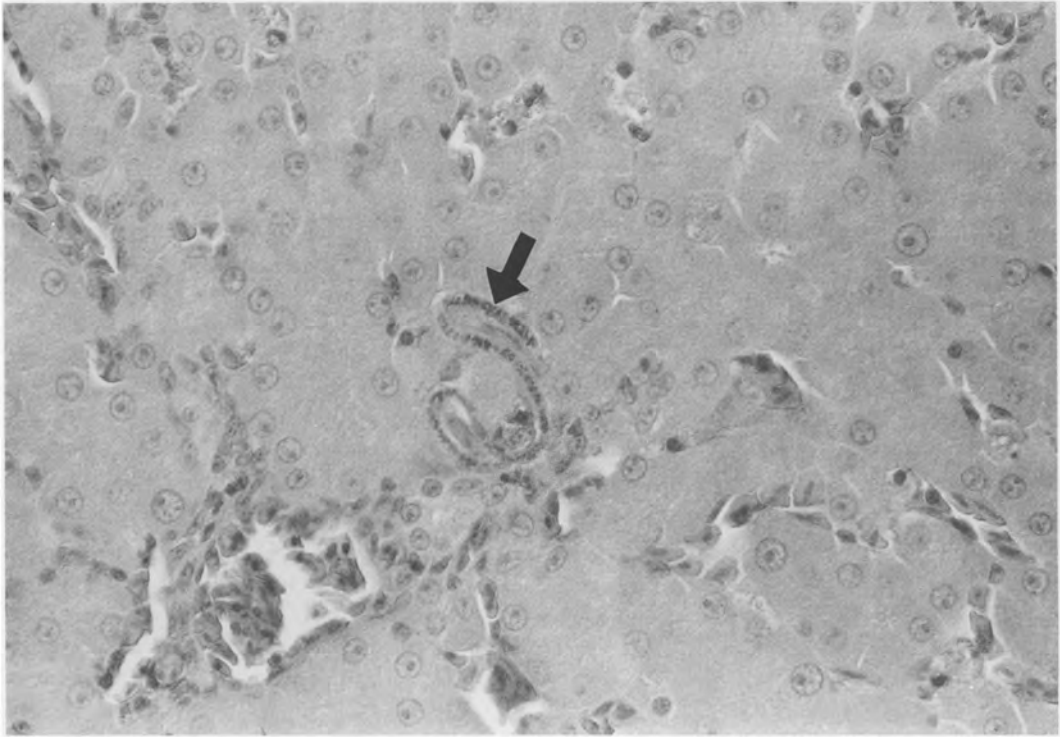


Figure 2. Liver with a microfilarial *Paronchocerca tonkinensis* (arrow) and no apparent host tissue reaction. H&E, $\times 400$.

Hematologic findings

Blood samples were collected as described by Hawkey and Samour⁷ from bird Nos. 3 and 5 shortly before they died and from the five surviving birds 10 days after arrival. Differential white blood cell counts gave the following mean percentage compositions: neutrophils, 69 (± 5.9); lymphocytes, 18 (± 4.0); monocytes, 8 (± 1.7); eosinophils, 2.5 (± 2.4); and basophils, 2.8 (± 1.9). Total white blood cell counts were not evaluated, although the blood films suggested a high value. The mean thrombocyte count was 68 (± 54) thrombocytes per 100 white blood cells. The red cell picture was one of mild to moderate anisocytosis, mild polychromasia, and mild poikilocytosis. *Haemoproteus* spp. were seen in two birds (No. 5 and one of the surviving birds, No. 6) and identified as *H. telfordi* and *H. tenderoi*. Sections of lung, liver, heart, and kid-

ney from bird No. 5 were extensively examined under $\times 100$ oil immersion, but no evidence of hemoproteid schizonts was found. This suggested that either the schizonts for this species have a predilection for skeletal muscle or were simply not present in the samples of tissue available.

Serology results

Serum samples from four of the surviving birds were submitted to the Dubai Veterinary Research Laboratory for Newcastle disease hemagglutination inhibition testing. One sample gave a titre of 1:4, and the other three were negative.

DISCUSSION

Rupture of the aorta or atrium is a well-known condition in fast-growing domestic species such as the turkey.⁹ Its exact etiology is unknown, although systemic hyperten-

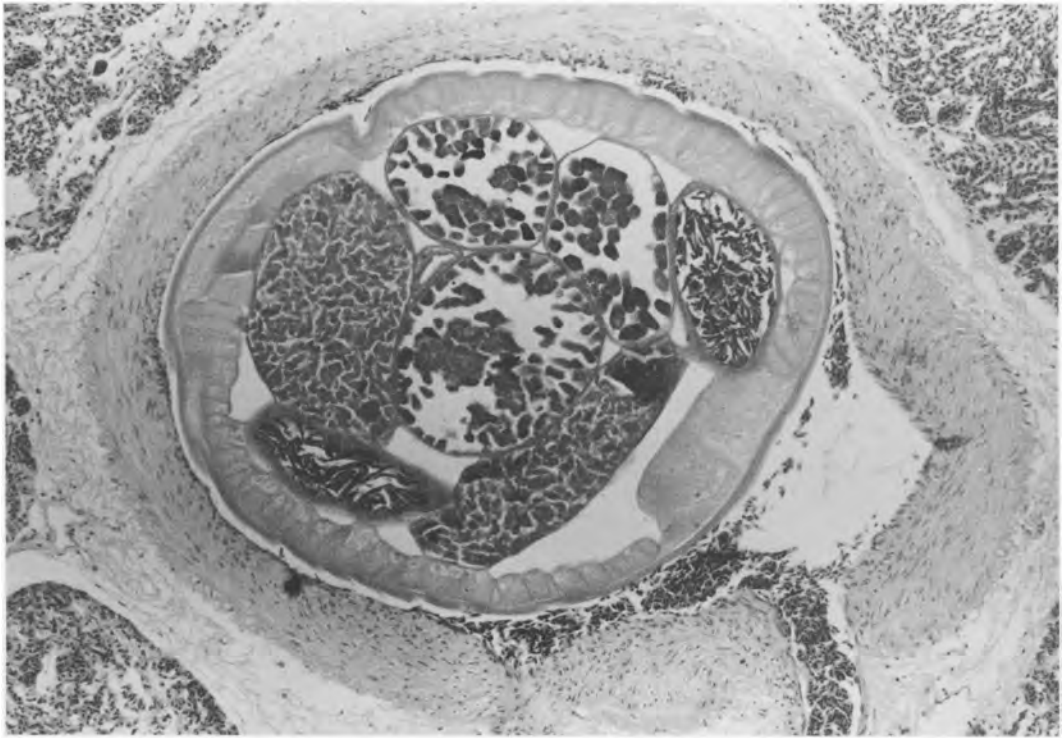


Figure 3. Pulmonary artery with lumen occupied by an adult *Paronchocerca tonkinensis*. H&E, $\times 100$.

sion, dietary protein, fat, and copper imbalances are possible causes.^{12,13} Nonperforating rupture of the heart apex with hemopericardium has been recorded in three capercaillie (*Tetrao urogallus*) reared in captivity.³ Capercaillie show high levels of anxiety and excitability in response to stimuli such as handling. Tachycardia, violent myocardial contraction, local ischaemia, or capture myopathy may have been underlying factors in the cardiac rupture.³ The cause of myocardial rupture and hemopericardium in the rufous-crested bustard described here is unknown, although it seems likely that the stress of capture, handling, and poor transportation conditions may have caused systemic hypertension. Additionally the presence of large numbers of adult *Paronchocerca* sp. in the pulmonary arteries (Fig. 3) may have caused a degree of right ventricular heart failure, and the numerous microfilariae seen in the ventric-

ular wall may have affected the perfusion of the myocardium. Whether the presence of microfilariae caused the focus of myocardial degeneration seen in the ruptured heart is not clear, although myocardial degeneration associated with microfilariae has been reported in other species.⁴ The presence of microfilariae in the living bird can be demonstrated by microscopic examination of a peripheral blood smear using routine stains, and this might be a useful technique for screening groups of birds for infection and subsequent treatment.

Heartworm was recorded in the frozen carcass of a rufous-crested bustard examined postmortem at Al Ain Zoo in 1993 (Nicholls and Bailey, unpubl. obs.). In this bird the origin and clinical history were not available, but it may have been a member of the captive breeding population at Al Ain Zoo that had originated from the wild some years earlier. Furley⁵ examined large num-

bers of bustards imported into Al Ain Zoo in the early 1980s and reported finding 3-cm-long nematodes in the ventricle of a newly imported white-bellied bustard (*Eupodotis senegalensis*), but no identification of the parasite was undertaken. The genus *Paronchocerca* has been reviewed by Bartlett and Anderson,¹ and *P. tonkinensis* has been described in *Ardeola bacchus*, *Ardea cinerea*, *Botaurus stellaris*, *Egretta garzetta*, *Gorsachius melanolophus thomasi*, and *Ardea herodias*.⁶ The mode of transmission of *Paronchocerca* sp. is poorly understood, although lice have been identified as intermediate hosts of heartworms in swans.^{2,15} Although lice have been found on recently imported bustards, none were seen on the bustards described in this report. The presence of adult heartworms in the right ventricle and pulmonary artery has been associated with thickening of the pulmonary arteries, pulmonary arterial thrombosis, and myocardial degeneration.⁴ The large numbers of heartworm found in some bustards suggest a pathogenic role in these individuals, and Seegar¹⁴ found that parasitism of whistling swans (*Cygnus columbianus columbianus*) by heartworm was associated with significant weight loss, indicating that preventive treatment with levamisole could have a useful management role in bustard husbandry.

The mean body weight for captive rufous-crested bustards is 600 g for females (range, 470–760 g) and 670 g for males (range, 600–770 g) (Bailey, unpubl. data). The body weights of all the bustards described in this study were below average (mean male weight, 461 g; mean female weight, 422 g), and one female (No. 1) was more than 30% below the average weight for captive birds. Transportation conditions of bustards imported into the UAE are often inadequate, and little consideration is given to the adequate provision of food or water during transit (Bailey, unpubl. obs.).

The mortality of bustards imported into the UAE is high. A survey of mortality in houbara bustards (imported from Pakistan

to Al Ain Zoo during an 11-wk period from February 1993 to April 1993 (J. Naldo, unpubl. data) revealed that 21 of 123 birds died, an overall mortality of 17%. These findings have important implications for the husbandry of bustards in captive breeding programs.

Acknowledgments: We thank our colleagues in the National Avian Research Centre (NARC), in particular H. H. Sheik Khalifa bin Zayed Al Nahyan, H. H. Sheikh Mohammed bin Zayed Al Nahyan, and Mr. M. al Bowardi, the managing director, for their personal interest and support of this work. We also thank Dr. Ullie Wernery from Dubai Veterinary Research Laboratory for the serologic studies; Mike Hart from J. S. Pathology, United Kingdom, for reading the blood films; Dr. M. A. Pierce for identifying the blood parasites; and Dr. M. Nael and Mr. P. Divakaran from the Al Ain Zoo for their assistance during this study. Emma Newstead prepared the histologic sections, and Dr. R. Hornby reviewed the manuscript.

LITERATURE CITED

1. Bartlett, C. M., and R. C. Anderson. 1986. *Paronchocerca struthionus* n. sp. (Nematoda: Filarioidea) from ostriches (*Struthio camelus*), with a redescription of *Paronchocerca ciconarum* Peters, 1936 and a review of the genus. *Can. J. Zool.* 64: 2480–2491.
2. Cohen, S., M. T. Greenwood, and J. A. Fowler. 1991. The louse *Trinotron anserinum* (Amblycera: Phthiraptera), an intermediate host of *Sarconema eurycera* (Filarioidea: Nematoda), a heartworm of swans. *Med. Vet. Entomol.* 5: 101–110.
3. Domingo, M., I. Marco-Sanchez, A. J. Marco-Valle, and M. Pumarola. 1991. Heart rupture and haemopericardium in capercaillie (*Tetrao urogallus*) reared in captivity. *Avian Pathol.* 20: 363–366.
4. Ensley, P. K. 1978. Levamisole hydrochloride for treatment of *Paronchocerca ciconarum* microfilariae in a marabou stork. *J. Am. Vet. Med. Assoc.* 173: 1246–1248.
5. Furley, C. 1980. Veterinary Problems in Bustards. National Avian Research Centre, Abu Dhabi, United Arab Emirates.
6. Greve, J. H., and D. L. Graham. 1980. Heartworm (*Chinesocerca tonkinensis*) in a wild great blue heron (*Ardea herodias*) in Iowa. *Proc. Helminthol. Soc. Washington* 47: 269.
7. Hawkey, C., and J. H. Samour. 1988. The value of clinical hematology in exotic birds. In: Jacobson, E. R., and G. V. Kollias, (eds.). *Contemporary Issues in*

Small Animal Practice, vol. 9. Churchill Livingstone, New York, New York. Pp. 110–111.

8. Johnsgard, P. A. (ed.). 1991. Bustards, Hemipods and Sandgrouse—Birds of Dry Places. Oxford Univ. Press, Oxford, England, United Kingdom. P. 189.
9. Julian, R. J. 1990. Cardiovascular disease. *In*: Jordan, F. T. W. (ed.). Poultry Diseases. Bailliere Tindall, London, England, United Kingdom. P. 338.
10. Nicholls, P. K., T. A. Bailey, J. H. Samour, J. Naldo, J. Howlett, and M. D'Aloia 1993. Guidelines for the Post-mortem Examination of Bustards. National Avian Research Centre, Abu Dhabi, United Arab Emirates.
11. Osborne, P., N. Collar, and P. Goriup. 1984. Bustards. Dubai Wildlife Research Center, Dubai, United Arab Emirates.
12. Pritchard, W. R., W. Henderson, and C. W. Beall. 1958. Experimental production of dissecting aneurysms in turkeys. *Am. J. Vet. Res.* 19: 696–705.
13. Riddell, C. 1991. Developmental metabolic and miscellaneous disorders. *In*: Calnek, B. W. (ed.). Poultry Diseases, 9th ed. Iowa State Univ. Press, Ames, Iowa. Pp. 827–862.
14. Seegar, W. S. 1979. Prevalence of parasitic heartworms in swans in England. *Wildfowl* 30: 147–150.
15. Seegar, W. S., E. L. Schiller, W. J. L. Slader, and M. Trapis. 1976. A mallophaga, *Trinoton anserinum*, as a cyclodevelopmental vector for a heartworm parasite of waterfowl. *Science* 194: 739–740.

Received for publication 23 March 1995.