

Multinodular Goiter in Children: an Important Pointer to a Germline *DICER1* Mutation

Rath SR^{1,2}, Charles A³, Powers N⁴, Baynam G^{2,5,6}, Jones T^{1,2,7}, Priest J⁸, Foulkes WD⁹, Choong CSY^{1,2}

1. Department of Endocrinology and Diabetes, Princess Margaret Hospital for Children; 2. School of Paediatrics and Child Health, University of Western Australia; 3. Department of Pathology, Princess Margaret Hospital for Children; 4. Department of Diagnostic Imaging, Princess Margaret Hospital for Children; 5. Genetic Services of Western Australia, Princess Margaret and King Edward Memorial Hospitals; 6. Institute for Immunology and Infectious Diseases, Murdoch University; 7. Telethon Institute for Child Health Research, Perth, WA; 8. Minneapolis, MN, USA; 9. Program in Cancer Genetics, Department of Oncology and Human Genetics, McGill University, Montreal, QC

A 9 year old boy with history of cystic nephroma excised at 20 months of age (Figure 1) presented with a neck swelling. Examination revealed a 30 mm x 30 mm firm, nontender mass in the left lobe of the thyroid. There were no associated compressive or obstructive findings and no cervical lymphadenopathy. Thyroid function and thyroid autoantibody titers were normal. Ultrasound demonstrated the thyroid gland replaced by cysts and nodules (Figure 1, Supplemental Figure 1). Fine needle aspiration of the dominant nodule was categorised as indeterminate according to the Bethesda Thyroid Cytopathology Reporting System (1), however cytopathological features favored a colloid nodule as part of a multinodular goitre (MNG) showing papillary hyperplasia (Supplemental Figure 2.).

Twelve months earlier, the proband's father had noted a similar neck swelling and MNG was diagnosed based on clinical and radiological findings (Supplemental Figure 3).

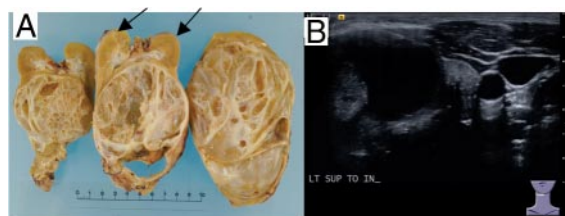


Figure 1. A. Gross pathology of proband's nephrectomy specimen: multiloculated cysts, effacing normal parenchyma (arrows) consistent with CN. CN is strongly associated with PPB and *DICER1* mutations. **B.** Ultrasound of proband's thyroid (left lobe), demonstrating multiple large cysts and nodules.

FNA demonstrated a benign cytologic pattern consistent with colloid nodules. The deceased paternal grandfather had a verbally reported but unconfirmed history of thyroidectomy. Neither the proband nor his father had thyroid surgery, electing instead to undertake regular thyroid sonographic surveillance.

Review of the proband's chest CT scans (performed at 20 months of age), identified pulmonary cysts consistent with pleuropulmonary blastoma (PPB) type Ir. Notably, his father had been diagnosed with a lung cyst at age 13, following presentation with acute chest pain, likely also PPB type Ir (figure 2).

Both individuals provided informed consent for institutionally-approved genetic research and this case report. They were found to carry a novel germ line *DICER1* mutation: c.5221_5232delAACAACACCATC.

DICER1 syndrome is a recently described, highly pleiotropic, variably penetrant, autosomal dominant tumor predisposition syndrome (2), caused by inactivating germ line *DICER1* mutations (3). It is associated with rare cancers and dysplasias, occurring typically from birth to age 20 years: most frequently PPB (4), CN, ovarian Sertoli-Leydig cell tumors and MNG (5). Thyroid disease (nodular hyperplasia, cysts, MNG) may emerge as the most frequent presentation of this syndrome.

DICER1 is a cytoplasmic RNase III endoribonuclease, producing mature microRNAs: small, noncoding RNAs that post-transcriptionally modulate messenger RNA (mRNA) expression and are critical in early somatic de-

Abbreviations:

ISSN Print 0021-972X ISSN Online 1945-7197
 Printed in U.S.A.
 Copyright © 2014 by the Endocrine Society
 Received October 29, 2013. Accepted March 4, 2014.

velopment (6). Interestingly, *DICER1* shares a locus with the familial MNG gene (*MNG1*) on chromosome 14q (7).

Childhood and/or familial MNG suggest *DICER1* Syndrome, particularly when other highly characteristic diseases like CN or lung cysts co-occur. Genetic counseling is strongly recommended (www.ppbregistry.org) prior to *DICER1* mutation analysis. The prevalence of differentiated thyroid carcinoma in *DICER1*-associated nodular thyroid disease is unknown, however follicular thyroid carcinoma has been reported following high dose chemotherapy and hemopoetic stem cell transplantation for treatment of PPB (8). Wider recognition of the *DICER1* syndrome will shed light on the natural history of the associated thyroid disease and facilitate early detection of other tumors, including PPB.

Acknowledgments

Address all correspondence and requests for reprints to: Shoshana Rath, Phone: +61 413626777, E-mail: nooshi.rath@health.wa.gov.au, Princess Margaret Hospital for Children, Roberts Rd Subiaco, WA Australia 6008.

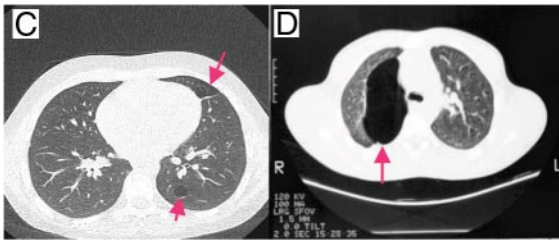


Figure 2. Computed chest tomographic images of proband (C) and his father (D) revealing pulmonary cysts consistent with PPB type 1r.

The authors have nothing to disclose.
This work was supported by .

References

1. Cibas ES, Ali SZ, Conference NCITFSotS. The Bethesda System For Reporting Thyroid Cytopathology. *American journal of clinical pathology*. 2009 Nov;132(5):658–65. PubMed PMID: 19846805.
2. Choong CS, Priest JR, Foulkes WD. Exploring the endocrine manifestations of *DICER1* mutations. *Trends Mol Med*. 2012 Sep;18(9):503–5. PubMed PMID: 22867905.
3. Hill DA, Ivanovich J, Priest JR, Gurnett CA, Dehner LP, Desruisseau D, et al. *DICER1* mutations in familial pleuropulmonary blastoma. *Science*. 2009 Aug 21;325(5943):965. PubMed PMID: 19556464. Pubmed Central PMCID: 3098036.
4. Hill DA, Jarzembowski JA, Priest JR, Williams G, Schoettler P, Dehner LP. Type I pleuropulmonary blastoma: pathology and biology study of 51 cases from the international pleuropulmonary blastoma registry. *The American journal of surgical pathology*. 2008 Feb;32(2):282–95. PubMed PMID: 18223332.
5. Slade I, Bacchelli C, Davies H, Murray A, Abbaszadeh F, Hanks S, et al. *DICER1* syndrome: clarifying the diagnosis, clinical features and management implications of a pleiotropic tumour predisposition syndrome. *Journal of medical genetics*. 2011 Apr;48(4):273–8. PubMed PMID: 21266384.
6. Bahubeshi A, Tischkowitz M, Foulkes WD. miRNA processing and human cancer: *DICER1* cuts the mustard. *Sci Transl Med*. 2011 Nov 30;3(111):111ps46. PubMed PMID: 22133720.
7. Rio Frio T, Bahubeshi A, Kanellopoulou C, Hamel N, Niedziela M, Sabbaghian N, et al. *DICER1* mutations in familial multinodular goiter with and without ovarian Sertoli-Leydig cell tumors. *JAMA*. 2011 Jan 5;305(1):68–77. PubMed PMID: 21205968. Pubmed Central PMCID: 3406486.
8. Shin SH, Yoon JH, Son MH, Kim SJ, Park SY, Kim HY, et al. Follicular thyroid carcinoma arising after hematopoietic stem cell transplantation in a child with pleuropulmonary blastoma. *Thyroid : official journal of the American Thyroid Association*. 2012 May;22(5):547–51. PubMed PMID: 22468940.